

# Effect of rapamycin combined with nedaplatin in the treatment of bladder cancer and its influence on angiogenesis and invasion

Jiansheng Wang<sup>1</sup>, Yi Zhang<sup>2\*</sup>, Yujuan Zhang<sup>1</sup>, Longfeng Chen<sup>1</sup>

## Abstract

**Objective** To investigate the efficacy of rapamycin combined with nedaplatin in the treatment of bladder cancer and its influence on angiogenesis and invasion. **Methods** 96 cases of bladder cancer patients in our hospital and Shanghai Fudan clinical pathological diagnosis center from January 2015 to December 2019 were retrospectively analyzed. They were divided into two groups according to different preoperative chemotherapy methods, 48 cases in each group. The observation group was given rapamycin combined with nedaplatin chemotherapy, while the control group was only given nedaplatin chemotherapy. After 2 cycles of continuous chemotherapy, extensive hysterectomy and pelvic lymph node dissection were implemented. The clinical efficacy, surgical conditions, microvessel density (MVD), vascular endothelial growth factor (VEGF), type 1, 3a, 8 and  $\beta$  - Catenin in pathological and healthy tissues were compared between the two groups. **Result** After treatment, the total remission rate of the observation group was 77.08% (37/48), which was significantly higher than 52.08% (25/48) of the control group ( $P < 0.05$ ); there was no significant difference in the operation time and intraoperative blood loss between the two groups ( $P > 0.05$ ). The rates of vascular invasion, parauterine invasion and lymph node metastasis in the observation group were 2.08% (1/48), 4.17% (2/48), 4.17% (2/48), which were significantly lower than 14.58% (7/48) of the control group). MVD and VEGF in the lesions of the two groups were significantly higher than those in the healthy tissues ( $P < 0.05$ ), but the MVD and VEGF in the lesion tissues of the observation group were significantly lower than those in the control group, and the Pearson correlation analysis showed that there was a positive correlation between MVD and VEGF ( $P < 0.05$ ); Wnt1, Wnt3a, wnt8 and  $\beta$  - Catenin in in the lesion tissues of the two groups were significantly higher than those in the healthy group However, the levels of Wnt1, Wnt3a, wnt8 and  $\beta$  - Catenin in the lesion tissues of the observation group were significantly lower than those of the control group ( $P < 0.05$ ); there were no grade III to IV liver and kidney injury in the two groups during the treatment, and there was no significant difference in the incidence of bone marrow suppression and gastrointestinal reaction between the two groups ( $P > 0.05$ ). **Conclusion** rapamycin combined with nedaplatin has a significant effect in bladder cancer patients, which can effectively regulate tumor angiogenesis and cancer cell invasion, and improve the disease remission rate, with less side effects and high safety.

**Keywords:** bladder cancer; rapamycin; nedaplatin; angiogenesis; invasiveness

Bladder cancer is a very common Department of Urology tumor in recent years. Incidence rate is becoming younger in recent years. In early stage of bladder cancer, both positive and radical radiotherapy can achieve satisfactory results. But stage B2 ~ B II is easy to appear distant and local metastasis and

1. Department of Urology, Hangzhou Xixi hospital, Affiliated .Hospital of Zhejiang University of traditional Chinese medicine, Hangzhou City, Zhejiang Province, China 310023

2. Operating room, Hangzhou Xixi hospital, Affiliated Hospital of Zhejiang University of traditional Chinese medicine , Hangzhou City, Zhejiang Province, China 310023

\*Correspondence Email: 1317488654@qq.com

\*Correspondence Author: Yi Zhang

infiltration. Chemotherapy is very important [1-2]. Cisplatin is one of the most commonly used chemotherapeutic drugs in clinic, but it has many side effects in recent and long term, which often causes intolerance and is difficult to adhere to treatment. Nedaplatin, as the second generation of platinum compounds, has been gradually applied to the combined chemotherapy of bladder cancer in recent years, and has a trend of gradually replacing cisplatin [3]. Rapamycin, as a new type of macrocyclic lipid immunosuppressant, has been widely used in the treatment of a variety of tumors. According to basic research, rapamycin can inhibit the growth of bladder cancer, skin cancer, cervical cancer and other tumors, and can inhibit cell proliferation and induce cell apoptosis [4-5]. However, there are few reports about rapamycin combined with nedaplatin. Therefore, the purpose of this study is to investigate the efficacy of rapamycin combined with nedaplatin in the treatment of bladder cancer, and to observe its influence on angiogenesis and invasion.

## 1. Data and methods

### 1.1 general information

Methods: 96 cases of bladder cancer patients in our hospital and Shanghai Fudan clinical pathological diagnosis center from January 2015 to December 2019 were retrospectively analyzed. They were divided into two groups by different preoperative chemotherapy methods, 48 cases in each group. The observation group was given rapamycin combined with nedaplatin chemotherapy, and the control group was given nedaplatin chemotherapy. The general information of the two groups is shown in Table 1, with no significant difference ( $P > 0.05$ ), which is comparable.

Inclusive criteria: 1) in accordance with the diagnostic criteria of bladder cancer [6], and confirmed by postoperative histopathological examination; 2) stage I B2 ~ II B, local tumor diameter  $> 4\text{cm}$ ; 3) age  $\leq 70$  years old; 4) complete clinical data. Exclusion criteria: 1) severe dysfunction of liver and kidney function; 2) patients complicated with immune system, hematological system diseases or acute chronic diseases; 3) previous over chemoradiotherapy and surgery; 4) abnormal bone marrow function; 5) chemotherapy contraindications; 6) withdrawal from treatment.

**Table 1** Comparison of general data between two groups

group	Observation group	Observation group	Statistical value	P value
Number of cases	48	48		
Age (years)	45.98±7.65	46.12±7.47	t=0.091	0.928
Course of disease (years)	2.30±0.31	2.34±0.29	t=0.653	0.516
Maximum diameter of tumor(cm)	5.09±0.75	5.06±0.79	t=0.191	0.849
FIGO staging of bladder cancer	I b2 leve	17(35.42)		
	IIa leve	24(50.00)	u=0.619	0.536
	IIb leve	7(14.58)		
Pathological grade of tumor	I level	13(27.08)		
	II level	25(52.08)	u=0.739	0.46
	III level	10(20.83)		
Histological types	Adenocarcinoma	10(20.83)	$\chi^2=0.236$	0.627
	Squamous cell carcinoma	21(43.75)	$\chi^2=0.043$	0.837

### 1.2 method

Dexamethasone was given orally in both groups 12 hours before chemotherapy, and theofenamine and cimetidine were given 30 minutes before chemotherapy. Metoclopramide and tropisetron were given to resist vomiting during chemotherapy.

The control group was given nedaplatin (specification: 10mg, manufacturer: Nanjing

xianshengdongyuan Pharmaceutical Co., Ltd., Guoyao Zhunzi h20030884) on the first day of the chemotherapy cycle. The dose of 80 / m<sup>2</sup> was added into 500ml 0.9% sodium chloride solution, intravenous drip for 3 h, and then the infusion was continued to be 1000ml after the infusion. The dosage of nedaplatin in the observation group was the same as that of the control group, and was treated with rapamycin (specification: 50mg, manufacturer: sigma

company, batch No.: hy-10219). The dose of nedaplatin was 10ml dissolved in 500ml 0.9% sodium chloride solution for intravenous drip.

After 2 cycles of continuous chemotherapy, extensive hysterectomy and pelvic lymphadenectomy were performed in both groups, and the distance from the edge of tumor tissue to the edge of tumor tissue was more than 1.5 cm.

### 1.3 observation index

1.3.1 record the operation conditions, including the operation time, intraoperative blood loss, pathological examination and the incidence of vascular invasion and parauterine infiltration,

1.3.2 Tumor microvessel density (MVD): the tumor tissue and healthy tissue around the lesion were extracted, and immunohistochemical staining (SP) was performed to detect the expression of CD34 + as MVD. The main steps were as follows: routine paraffin embedded section, dewaxing, washing in water and phosphate buffer (PBS) and microwave thermal repair, using 3.0% hydrogen peroxide to remove endogenous peroxidase. The results showed that 1 antibody (Abcam, ab8536) was inactivated and blocked with goat serum; 1 antibody (Abcam, ab8536), diluted with PBS, incubated overnight at 4 °C, washed with PBS, and incubated at 37 °C for 15min, diaminobenzidine was used to develop color, hematoxylin was re stained, and the cells with brown color were positive cells; under the low power microscope, five ideal staining regions were selected. The number of total vessels / 5 was the final result.

1.3.3 The lesion tissue and healthy tissue were mixed with 0.9% sodium chloride injection in the ratio of 1:9. After electric shaking, centrifugation was performed at the speed of 3000r / min for 15min. The upper serum was extracted. The vascular endothelial growth factor (VEGF), extracellular factor protein

(Wnt) type 1, 3a, 8 and  $\beta$  - Catenin were detected by au5800 automatic biochemical analyzer produced by Beckman Coulter company in Germany. The expression of  $\beta$  - Catenin was detected by enzyme-linked immunosorbent assay (ELISA);

1.3.4 the side effects were recorded.

### 1.4 evaluation criteria of efficacy

According to the literature [6], complete remission (CR): the lesion disappeared and lasted for more than 1 month; partial remission (PR): the lesion diameter was reduced by more than 30% and maintained for more than 1 month; stable (SD): the lesion diameter decreased by less than 30% or increased by less than 20%; progression (PD): the lesion diameter increased by more than 20%, and even new lesions appeared. Cr + PR was the total remission rate.

### 1.5 statistical analysis

Using SPSS18.0 software package, the measurement data were all normal distribution, expressed by mean  $\pm$  standard deviation ( $\pm$  s). The independent sample t test was used for comparison between groups, the count data was expressed as rate,  $\chi^2$  test, rank sum test for rank data, Pearson correlation analysis was used for correlation analysis of MVD and VEGF,  $P < 0.05$  indicated that the difference was statistically significant.

## 2. Results

### 2.1 comparison of clinical efficacy between the two groups

After treatment, the total remission rate of the observation group was 77.08%, which was significantly higher than 52.08% of the control group ( $P < 0.05$ ), as shown in Table 2.

**Table 2** Comparison of clinical efficacy between the two groups [n (%)]

group	Number of cases	CR	PR	SD	PD	Total remission rate
Observation group	48	8(16.67)	29(60.42)	9(18.75)	2(4.17)	37(77.08)
control group	48	2(4.17)	23(47.92)	17(35.42)	6(12.50)	25(52.08)
u/ $\chi^2$ value			u=2.922			$\chi^2=6.558$
P value			P=0.004			P=0.010

### 2.2 comparison of operation conditions between the two groups

There was no significant difference in operation

time and intraoperative blood loss between the two groups ( $P > 0.05$ ). The rates of vascular invasion, parauterine invasion and lymph node metastasis in the observation group were significantly lower than

those in the control group ( $P < 0.05$ ), as shown in Table 3.

**Table 3** Comparison of operation conditions between the two groups [ $\pm s, n (\%)$ ]

group	Number of cases	Operation time(h)	Intraoperative blood loss(ml)	Vascular invasion	Parauterine infiltration	Lymph node metastasis
Observation group	48	3.17 $\pm$ 0.57	489.52 $\pm$ 76.91	1(2.08)	2(4.17)	2(4.17)
control group	48	3.09 $\pm$ 0.62	496.17 $\pm$ 75.10	7(14.58)	8(16.67)	9(18.75)
Statistical value		t=0.658	t=0.429	$\chi^2=4.909$	$\chi^2=4.019$	$\chi^2=5.031$
P value		0.512	0.669	0.027	0.045	0.025

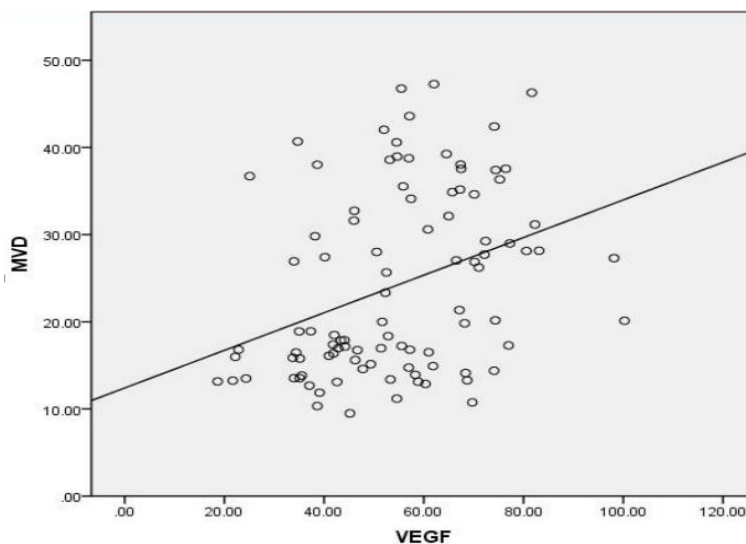
**2.3 comparison of MVD and VEGF between the two groups**

MVD and VEGF in lesion tissues of two groups were significantly higher than those in healthy tissues ( $P < 0.05$ ), but MVD and VEGF in lesion tissues of

observation group were significantly lower than those in control group ( $P < 0.05$ ), and Pearson correlation analysis showed that there was a positive correlation between MVD and VEGF ( $R = 0.349, P < 0.05$ ), as shown in Table 4 and figure 1.

**Table 4** Comparison of MVD and VEGF between the two groups ( $\bar{x} \pm s$ )

group	Number of cases	MVD(strip /mm <sup>2</sup> )		VEGF(ng/L)	
		Focus tissue	Health Organization	Focus tissue	Health Organization
Observation group	48	14.85 $\pm$ 2.41*	6.17 $\pm$ 1.49	89.54 $\pm$ 15.40*	46.85 $\pm$ 4.75
control group	48	18.70 $\pm$ 3.05*	6.20 $\pm$ 1.42	104.23 $\pm$ 17.31*	47.10 $\pm$ 4.89
T value		6.862	0.101	4.393	0.254
P value		0.000	0.920	0.000	0.800



**Figure 1** scatter plot of correlation analysis between MVD and VEGF

**2.4 comparison of Wnt1, Wnt3a, wnt8 and  $\beta$  - Catenin between the two groups after operation**

Wnt1, Wnt3a, wnt8 and  $\beta$  - Catenin in lesions

of two groups were significantly higher than those in healthy tissues ( $P < 0.05$ ), but Wnt1, Wnt3a, wnt8 and  $\beta$  - Catenin in lesion tissues of observation group were

significantly lower than those of control group ( $P < 0.05$ ), as shown in Table 5.

**Table 5** Comparison of Wnt1, Wnt3a, wnt8 and  $\beta$  - Catenin between the two groups ( $\bar{x} \pm s$ )

group	Number of cases	Wnt1		Wnt3a		Wnt8		$\beta$ -catenin	
		Lesion tissue	Health Organization	Lesion tissue	Health Organization	Lesion tissue	Health Organization	Lesion tissue	Health Organization
Observation group	48	11.48±2.75*	3.37±0.54	16.89±2.40*	12.37±1.75	10.43±2.05*	2.49±0.23	27.54±4.12*	17.42±3.09
control group	48	16.57±2.34*	3.33±0.58	22.47±2.75*	12.44±1.72	15.17±2.46*	2.43±0.25	33.79±5.20*	17.29±3.17
T value		9.766	0.350	10.592	0.198	10.255	1.224	6.527	0.204
P value		0.000	0.727	0.000	0.844	0.000	0.224	0.000	0.839

### 2.5. Comparison of toxicity and side effects between the two groups

There was no significant difference in the

incidence of bone marrow suppression and gastrointestinal reaction between the two groups ( $P > 0.05$ ), and the above side effects were relieved after symptomatic treatment, as shown in Table 6.

**Table 6** Comparison of side effects between the two groups[n(%)]

Side effects	I ~ II degree		$\chi^2$ value	P value	III~IV degree		$\chi^2$ value	P value
	Observation group (n=48)	control group(n=48)			Observation group (n=48)	control group(n=48)		
Myelosuppression	8(16.67)	7(14.58)	0.079	0.779	1(2.08)	0(0.00)	1.011	0.315
Gastrointestinal reactions	7(14.58)	9(18.75)	0.301	0.583	2(4.17)	1(2.08)	0.344	0.558
Liver damage	2(4.17)	3(6.25)	1.044	0.307	0(0.00)	0(0.00)	-	-
Renal function injury	2(4.17)	1(2.08)	0.344	0.558	0(0.00)	0(0.00)	-	-

### 3. Discussion

Relevant studies have pointed out that for stage I B2 ~ II B bladder cancer with tumor diameter > 4cm, the probability of pelvic metastasis is as high as 35 ~ 80%. Due to the factors of large local tumor volume and high metastasis rate, it is difficult to obtain satisfactory resection rate by simple operation. In addition, the increase of hypoxia cells caused by large volume will also reduce the sensitivity of radiotherapy. Therefore, preoperative radiotherapy is difficult to kill sub clinical patients Bed metastasis and effectively reduce the tumor, increase the recurrence rate [7-8]. With the younger incidence of bladder cancer, the use of radical radiotherapy will affect ovarian function, and then affect the quality of life of young patients. In recent years, more scholars have gradually begun to pay attention to the preoperative chemotherapy drug treatment of bladder cancer. The purpose is to reduce the local tumor and reduce the tumor stage after chemotherapy, so as to provide favorable conditions for radical surgery and improve

the prognosis [9-10].

Nedaplatin is a new class of platinum preparations with wide anticancer spectrum and low toxicity to kidney and gastrointestinal tract. A randomized controlled trial conducted by niibe y et al. [11] confirmed that nedaplatin has more satisfactory antitumor activity than cisplatin, and the total effective rate of nedaplatin in the treatment of bladder cancer can be as high as 70.7%. Chen Yu et al. [12] also pointed out that Nedaplatin Combined with chemotherapy has fewer adverse reactions than cisplatin combined chemotherapy, which can significantly improve the treatment compliance of patients. Rapamycin is a newly discovered immunosuppressant in recent years, and it is a mammalian; rapamycin target protein (mTOR) specific inhibitor, according to the National Cancer Institute of the United States, has obvious inhibitory effect on the growth of ovarian cancer, breast cancer, renal cancer, leukemia and other tumor cell lines, but the application report of this drug in China is still less [13-14].

The results showed that the total remission rate of patients with rapamycin was 77.08%, which was significantly higher than 52.08% of patients using nedaplatin alone. Moreover, the rate of vascular invasion, parauterine invasion and lymph node metastasis were significantly lower than those of patients with nedaplatin alone. The mitotic cycle of tumor cells, combined with the anti-tumor effect of nedaplatin, the two drugs work together to create favorable conditions for surgery and improve the disease remission rate. Bahrami et al. [15] also pointed out that rapamycin combined with platinum drugs can significantly improve the killing effect of cancer cells, which is similar to this study.

Angiogenesis is not only the morphological basis of tumor, but also an important condition for the normal development of its biological behavior. VEGF is a kind of angiogenesis factor with high specificity, which can promote the proliferation, migration and transformation of vascular endothelial cells into new blood vessels, which can provide favorable conditions for the proliferation of tumor cells. At present, VEGF and its receptor have been used as therapeutic targets for many tumors, and some achievements have been made [16-17]. The results showed that the expression of MVD and VEGF in bladder cancer lesions was higher than that in healthy tissues, and there was a positive correlation between MVD and VEGF. VEGF mediated angiogenesis plays an important role in promoting the occurrence and development of bladder cancer. However, the expression of MVD and VEGF in the lesion tissue of patients combined with rapamycin was significantly lower than that of patients treated with nedaplatin alone. Wu Jiuling et al. [18] also pointed out that rapamycin can inhibit tumor angiogenesis by down regulating the transcription and expression of VEGF gene in tumor tissue of bladder cancer rats, and its combination with platinum drugs can improve its sensitivity and inhibit swelling more effectively. Tumor angiogenesis.

Wnt signaling pathway is also very important in the occurrence and development of tumors, which can reflect the malignancy and invasiveness of tumors. Wnt /  $\beta$  - Catenin is one of the classic pathways, which has been proved to be involved in the invasion and metastasis of bladder cancer [19]. Wei et al. [20] also showed that  $\beta$  - Catenin mainly takes Wnt1, 3a, and 8 as the promoter, which can be localized in chromosome 3p21-p22, and it is considered as the most important regulatory factor in Wnt pathway. When the expression of  $\beta$  - Catenin is too high, Wnt pathway will be open and promote tumor invasion

and metastasis. The results showed that the expression of Wnt1, Wnt3a, wnt8 and  $\beta$  - Catenin in bladder cancer lesions was significantly higher than that in healthy tissues, suggesting that there was an active Wnt /  $\beta$  - Catenin pathway in bladder cancer patients. However, the expression of Wnt1, Wnt3a, wnt8, and  $\beta$  - Catenin in tumor tissues of patients with rapamycin was lower than that in patients treated with nedaplatin alone. It is related to mTOR signaling pathway, while rapamycin can inhibit Akt and mTOR phosphorylation levels, and then inhibit Wnt /  $\beta$  - Catenin pathway [21], which may be one of the internal mechanisms for higher disease remission rate of combination therapy.

In addition, this study also showed that there was no grade III to IV liver and kidney function damage during the treatment period in both groups, and the incidence of bone marrow suppression and gastrointestinal reaction was mostly degree I to II, which could be alleviated after symptomatic treatment, suggesting that the combination of drugs did not increase drug toxicity and had high safety. However, the sample size of this study is small, and it still has certain limitations, and does not observe the effect of this method on the 3-year and 5-year survival rate of patients. It is still necessary to expand the sample size and extend the follow-up time in the future.

In conclusion, rapamycin combined with nedaplatin has a significant effect in bladder cancer patients, which can effectively regulate tumor angiogenesis and cancer cell invasion, and improve the disease remission rate, with less side effects and high safety.

#### Acknowledgement

Fund support: 20171226Y30, Fund of Hangzhou Science and technology guidance project.

#### Reference:

- [1] Zheng Xiaoxia, Li qiongzhen, Li Ling, et al. Analysis of prognosis and influencing factors of bladder cancer [J]. Journal of practical cancer, 2014,29 (03): 314-316
- [2] Jelen MM, Chen Z, Kocjan BJ, et al. Global genomic diversity of human papillomavirus 6 based on 724 isolates and 190 complete genome sequences[J]. J Virol, 2014, 88(13): 7307-7316.
- [3] Barra F, Lorusso D, Leone Roberti Maggiore U, et al. Investigational drugs for the treatment of cervical cancer[J]. Expert Opin Investig Drugs, 2017 , 26(4): 389-402.

- [4] Zhang Tao, Zheng Ximing, Zhou Linlin, et al. Effect of rapamycin on expression of 10 kinds of autophagy related miRNAs in RAW264.7 macrophages [J]. Chinese Journal of immunology, 2014,30 (08): 1055-1063
- [5] Dong P, Hao F, Dai S, et al. Combination therapy Eve and Pac to induce apoptosis in cervical cancer cells by targeting PI3K/AKT/mTOR pathways[J]. J Recept Signal Transduct Res, 2018, 38(1): 83-88.
- [6] People's Republic of China or national health and Family Planning Commission. Guidelines for standardized diagnosis and treatment of bladder cancer and precancerous lesions (Trial) [j]. China Medical Frontier Journal (Electronic Edition), 2013,5 (08): 37-46
- [7] Yang L, Yang P, Li D, et al. Comparison of safety and efficacy of laparoscopic versus abdominal radical hysterectomy in the treatment of patients with stage I a2-II b cervical cancer[J]. Chinese Journal of Obstetrics and Gynecology. 2015, 50(12): 915-922.
- [8] Qiao Youlin, Zhao Yuqian. Epidemiology and prevention of bladder cancer [J]. Chinese Journal of clinical medicine of women and children (Electronic Edition), 2015,11 (02): 1-6
- [9] Di Wen, Hong Zubei. Current situation and development trend of surgical treatment of bladder cancer [J]. Chinese Journal of practical urology and obstetrics, 2015,31 (06): 485-489
- [10] Kunos CA, Radivoyevitch T, Waggoner S, et al. Radiochemotherapy plus 3-aminopyridine-2-carboxaldehyde thiosemicarbazone (3-AP, NSC #663249) in advanced-stage cervical and vaginal cancers[J]. Gynecol Oncol, 2013, 130(1): 75-80.
- [11] Niibe Y, Onda T, Matsuo K, et al. Phase II Study of Concurrent Chemoradiotherapy Using Nedaplatin for Locally Advanced Uterine Cervical Carcinoma (KGROG0501): Final Results[J]. Anticancer Res, 2017, 37(12): 6983-6988.
- [12] Chen Yu, Zhou Ying, Zhang Xuefen, et al. Comparative analysis of nedaplatin or cisplatin combined with paclitaxel in adjuvant chemotherapy of bladder cancer [J]. Journal of Practical Obstetrics and Gynecology, 2015,31 (11): 862-865
- [13] eIF4E, are overexpressed and associated with HPV status in precancerous lesions and carcinomas of the uterine cervix[J]. Oncol Lett, 2016, 12(5): 3234-3240.
- [14] de Melo AC, Grazziotin-Reisner R, Erlich F, et al. A phase I study of mTOR inhibitor everolimus in association with cisplatin and radiotherapy for the treatment of locally advanced cervix cancer: PHOENIX I[J]. Cancer Chemother Pharmacol, 2016, 78(1): 101-109.
- [15] Bahrami A, Hasanzadeh M, Hassanian SM, et al. The Potential Value of the PI3K/Akt/mTOR Signaling Pathway for Assessing Prognosis in Cervical Cancer and as a Target for Therapy[J]. J Cell Biochem, 2017, 118(12): 4163-4169.
- [16] Yang Li, Cheng Xi. Research progress of molecular targeted therapy for bladder cancer [J]. Chinese Journal of cancer, 2015,25 (01): 73-80
- [17] Sharma M, Khan R, Aggarwal M, et al. Modulatory Effects of Chemoradiation on Angiogenic Factors and Laminin in Cervical Cancer: Link with Treatment Response[J]. Asian Pac J Cancer Prev, 2017, 18(11): 2937-2944.
- [18] Wu Jieling, Han Lu, Yang LiXiao. Effects of rapamycin combined with cisplatin on the growth of bladder cancer HeLa cells and the expression of HIF-1  $\alpha$  and VEGF [J]. Chinese Journal of cancer prevention and treatment, 2013,20 (14): 1075-1078
- [19] Li Chunyan, Gao Ning, Hou Yingchun. Classic Wnt signaling pathway and human tumor [J]. Chinese Journal of Biochemistry and molecular biology, 2014,30 (05): 447-452
- [20] Wei H, Zhang JJ, Tang QL. MiR-638 inhibits cervical cancer metastasis through Wnt/ $\beta$ -catenin signaling pathway and correlates with prognosis of cervical cancer patients[J]. Eur Rev Med Pharmacol Sci, 2017, 21(24): 5587-5593.
- [21] Chen L, Wang L, Shen H, et al. Anthelmintic drug niclosamide sensitizes the responsiveness of cervical cancer cells to paclitaxel via oxidative stress-mediated mTOR inhibition[J]. Biochem Biophys Res Commun, 2017, 484(2): 416-421.